

Three-dimensional Ultrasound Evaluation of Tongue Posture and Its Impact on Articulation Disorders in Preschool Children with Anterior Open Bite

[Sanda Lah Kravanja](#),¹ [Irena Hocevar-Boltezar](#),² [Maja Marolt Music](#),^{3,4} [Ana Jarc](#),² [Ivan Verdenik](#),⁵ and [Prof. Maja Ovsenik, D.M.D, Ph.D.](#)^{*,6}

[Author information](#) [Article notes](#) [Copyright and License information](#) [Disclaimer](#)

Abstract

[Go to:](#)

Introduction

Anterior open bite (AOB) is defined as the absence of contact of the anterior teeth when the posterior teeth are in contact.[1,2,3](#) It was established that heredity and several other factors (thumb and/or finger sucking, lip and tongue posture habits, impaired nasal breathing, and true skeletal growth abnormalities) play an important role in the etiology of this type of malocclusion.[4,5,6,7](#) The intrinsic vertical gap can cause difficulties in biting and chewing, affects the articulation and has unfavorable aesthetic and psychological consequences. Since 80% of specific speech movements are made in the anterior part of the mouth, it is not surprising that a relationship between articulation defects and malocclusion has long been assumed to exist.[8](#) Among great diversity of malocclusions, AOB is the most common malocclusion associated with articulation disorders.[9,10](#)

The tongue is a muscular, largely movable organ in the oral cavity, important for many oral and oropharyngeal functions. The tongue resting posture is believed to be even more important for the morphology of the growing jaws and the occlusion of the teeth than the tongue function during swallowing or speaking.[8](#) Specifically, the total time of swallowing and speaking is too short to affect the equilibrium of the forces acting on the teeth and the growth of jaws. The resting tongue with its tone and pressure on the adjacent structures represents one of the most important long-acting forces in the orofacial region. It has a great impact on the dentoalveolar development, dental occlusion, orofacial functions, the need for orthodontic treatment, and the posttreatment stability of the dental occlusion.[3,10](#) An incorrect tongue posture has long been reported as a primary etiologic factor in the development of malocclusion, including AOB and articulation disorders.[9,11](#)

The clinical evaluation of the tongue resting posture is routinely performed during clinical examination by ear, nose and throat (ENT) specialists and maxillofacial surgeons treating patients with clefts or orthognatic problems as well as by the orthodontists. However, clinical assessment of the tongue posture at rest without influencing and disturbing its natural posture is highly subjective in small growing children due to anatomical limitations.[8](#) Despite its subjectivity, it remains the golden standard in clinical practise. There have been no reports in the literature on the reliability of clinical assessment of the resting tongue posture by different professionals for the same group of children.

Three-dimensional ultrasonographic (3DUS) assessment of the tongue became recently an important tool for imaging tongue size, shape and posture, recording functional tongue movements during swallowing, feeding and speech.[12,13,14,15,16](#) With the use of 3DUS the objective resting tongue posture can be displayed even in preschool children.

The aim of the study was to present functional diagnostics using 3DUS assessment of resting tongue posture in comparison to its clinical assessment, and the associations between the improper tongue

posture, and AOB, orofacial, otorhinolaryngological characteristics, and articulation disorders in preschool children.

[Go to:](#)

Patients and methods

The study protocol was approved by the Republic of Slovenia National Medical Ethics Committee (protocol No. 96/04/13). The parents of all included children signed an informed consent for their and their children participation in the study.

Patients

In the first part of the survey the prevalence of AOB and articulation disorders was established by a cross-sectional epidemiological study in children attending kindergartens in municipality Tolmin. In total, 446 preschool children (236 boys, 211 girls), aged 3 to 7 years, were included.

The children with AOB (AOB group) and their parents were invited to participate in the second part of the study. The control group was recruited from the rest of the examined children without AOB. Seventy children without AOB were randomly selected and invited to further participate in the study as control group.

Patient examination procedures

In the first part of the study, all children were examined by the same orthodontist (SLK) during the kindergarten visits to detect AOB and articulation disorders. The parents gave their assessment of nasal breathing, possible articulation disorders and the necessity for speech therapy in their children.

In the second part of the study, all AOB and control group children were examined at the orthodontic clinic of the Community Dental Health Centre (Tolmin, Slovenia). During the intraoral examination the dental status, functional and morphological malocclusions were registered according to the method by Ovsenik *et al.*⁸ Alginate impressions and wax bite registrations were obtained and dental casts were prepared in the ortholab for documentation. The tongue posture at rest was recorded.

All AOB and control group children were examined by an experienced ENT specialist (IHB) and a speech therapist (AJ). The clinical ENT examination was performed with special emphasis on the resting tongue posture. In the case of an upper respiratory infection, the child was reinvited for the examination when he/she was healthy.

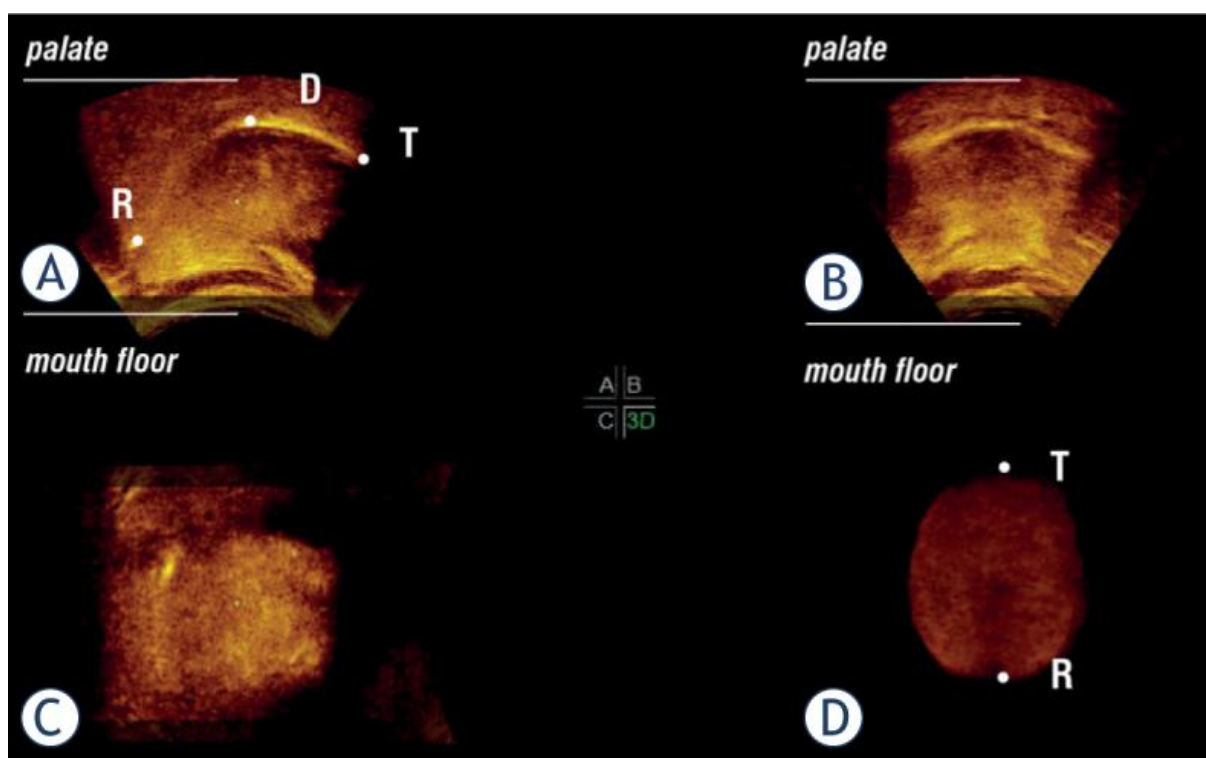
The speech therapist performed a three-position test for articulation disorders and registered possible articulation disorders.

Three-dimensional US examination

The children from both groups were invited for a 3DUS examination of the tongue posture by an experienced radiologist (MMM), Institute of Oncology in Ljubljana, with the use of the ultrasound system Voluson 730 Expert (General Electrics Healthcare, Kretztechnik, Zipf Austria) with a 3D convex transducer (RAB 2–5 MHz, GEH). Each child was seated in the dental chair, head positioned in the Frankfort horizontal line, parallel to the floor, and fixed with a strap. The 3D convex transducer was coated with an aqueous contact transmission gel and positioned on the skin of the mouth floor in the midsagittal line. Each child was asked to be relaxed and to remain still for 15 seconds; no instructions were given for the tongue posture. The recording procedure was repeated twice, using

the following parameters: 55-65-degree view, mechanical index 0.8, thermal index 0.3. The acquired data were transferred to a personal computer and visualized using the 4D View software version 5.0 (General Electrics Healthcare, Waukesha, Wisconsin). Referential 3D reconstructions obtained from 10 children without malocclusion in deciduous dentition were then used to compare the tongue posture for each child according to the method presented by Volk *et al.*¹⁷

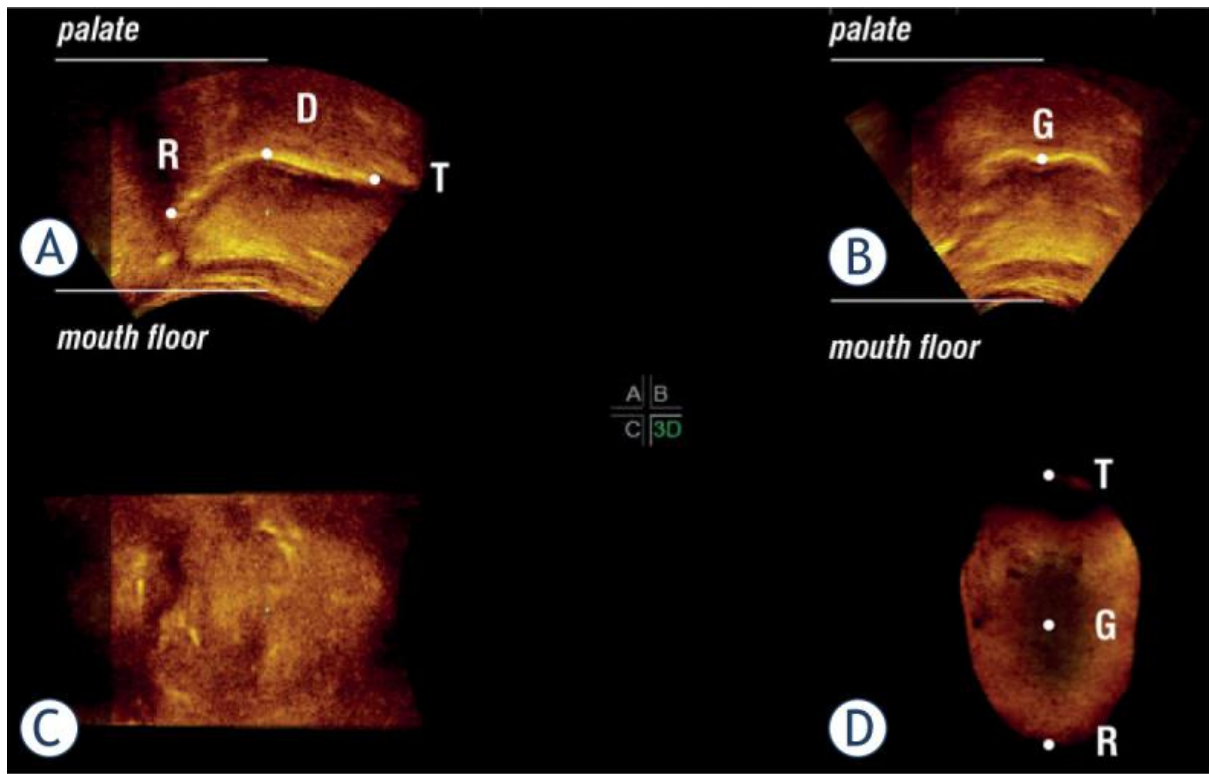
The correct resting tongue posture was recorded when the tip of the tongue was on the palate behind the upper incisors ([Figure 1](#)). In the improper resting tongue posture, the 3DUS displayed the tip of the tongue to be low on the mouth floor ([Figure 2](#)) according to the method by Volk *et al.*¹⁷ The US image of the tongue on the palate showed convexity of its dorsum ([Figure 1](#)), while when on the mouth floor the tongue dorsum showed a distinctive concavity with a central groove ([Figure 2](#)).



[Figure 1](#)

The US images of the child's resting tongue posture on the palate: sagittal view (**A**) antero - posterior (transverse) view (**B**); vertical view (**C**); 3D reconstruction of the tongue showing a convexity of the tongue dorsum (**D**).

D = Dorsum, R = Radix, T = Tip of the tongue



[Figure 2](#)

The US images of the child's resting tongue posture on the floor of the mouth: sagittal view **(A)**; anteroposterior (transverse) view **(B)**; vertical view **(C)**; 3D reconstruction of the tongue **(D)** showing a central groove (G) on the tongue dorsum.

D = Dorsum, R = Radix, T = Tip of the tongue

[Go to:](#)

Statistical analysis

All the collected data were analysed using the R statistical package (www.R-project.org). The data were analysed and compared using χ^2 -test or Fisher's exact test, t-test or nonparametric Mann-Whitney test. The multiple logistic regression model was used for the assessments of factors possibly associated with AOB. The results of the clinical assessment of the resting tongue posture performed by an orthodontist and an ENT specialist were compared with the results of US imaging using McNemar's test. The reliability of the clinical evaluation was calculated. The level of statistical significance was set at 0.05, and 95% confidence intervals were used.

[Go to:](#)

Results

AOB was found in 32 subjects (7.2%). The comparison of the general data and the parents' assessment of possible child's articulation disorders for the AOB children and the rest of the pediatric population without AOB are presented in [Table 1](#). There were significant differences between the groups in the occurrence of articulation disorders, and necessity for speech therapy.

Table 1

Comparison of the general data and the parents' assessment of the child's nasal breathing, the possible articulation disorders and the necessity for speech therapy between the group of children with anterior open bite (AOB) (N = 32) and the rest of the pediatric population without anterior open bite (N = 414)

Parameter	AOB (N = 32)	Without AOB (N = 414)	P
Age (years) ¹	4.9 (1.0)	5.0 (0.9)	0.548
Nasal breathing, day ²	31 (96.9%)	348 (84.1%)	0.056
Nasal breathing, night	29 (90.6%)	350 (84.5%)	0.382
Articulation disorder (parental assessment)	27 (84.4%)	108 (26.1%)	< 0.001
Necessity for speech therapy	13 (40.6%)	99 (23.9%)	0.018

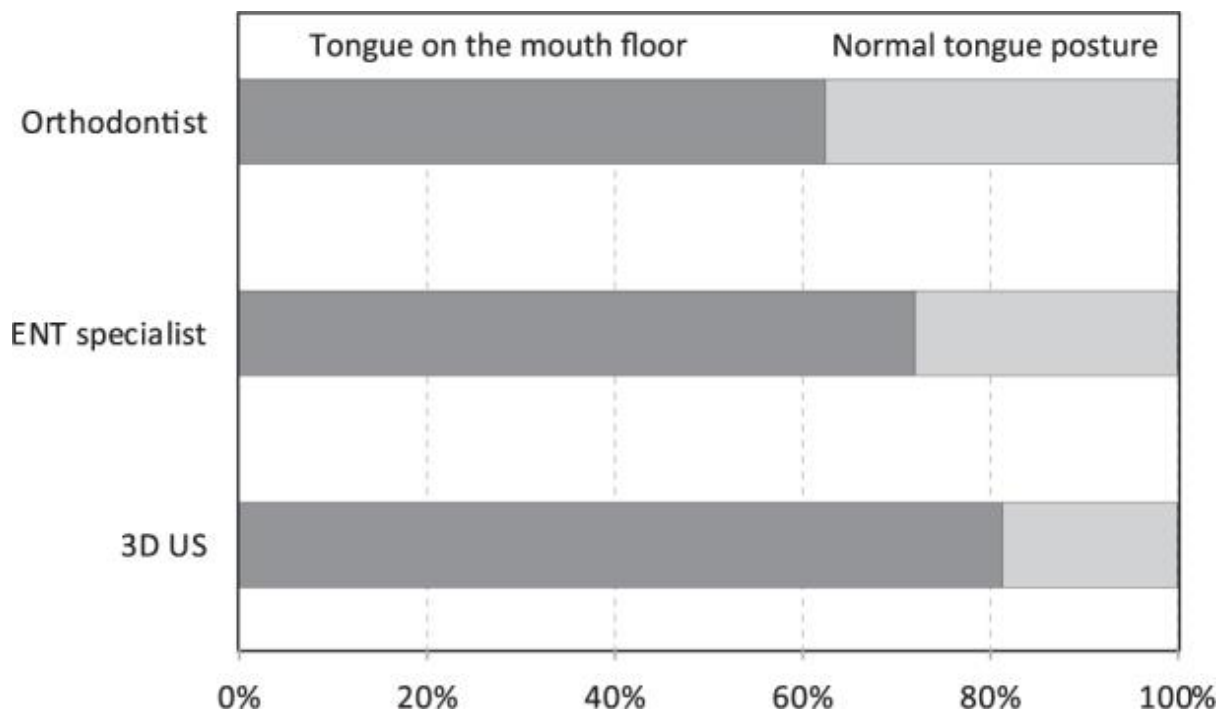
¹ For numerical variables mean and SD are given; ² for categorical number and percentage

The parents of 61.4% children out of the 70 randomly selected were willing to allow them to participate in the second part of the study. Thus, the control group consisted of 43 children.

All AOB and control group children underwent further examinations by the orthodontist, the ENT specialist, the speech therapist and the radiologist. The orthodontist found improper tongue posture on the floor of the mouth in 20 (62.5%) children from the AOB group, and in 9 (20.9%) children from the control group.

During the ENT examination, 12 AOB children and 14 control group children were found to have an upper airway infection. They were invited again for the examination three weeks later. All AOB children and only two control group children had a control ENT examination. Therefore, the findings of the ENT examination of the AOB group could only be considered for further analysis. In the AOB group, the ENT examination detected low tongue posture in 23 subjects (71.8%), incompetent lip closure in 22 subjects (68.8%), nasal breathing impairment in 19 subjects (59.4%), and hypertrophic adenoid/status post adenoidectomy in 17 subjects (53.1%).

The 3DUS assessment of the resting tongue posture showed the improper tongue posture on the mouth floor in 81.3% of the AOB children and in 25.6% of the control group children. When the results of the US-assessed tongue posture (26 children with improper posture) were compared with the ENT clinical assessment (23 subjects with improper posture) and clinical orthodontic assessment (20 children with improper posture), no significant differences were detected ($p = 0.549$ and $p = 0.180$, respectively; [Figure 3](#)).



[Figure 3](#)

Comparison of the assessment of the resting tongue posture by the clinical orthodontic examination, clinical ENT examination, and 3DUS examination in the AOB children.

The speech therapist and orthodontist found articulation disorders in 84.4% of AOB children and in 23.2% of control group children. In the AOB group, the most frequently detected articulation disorders were sigmatism (present in 25 children) and rhotacism (present in 16 children). Sixteen children had multiple articulation disorders. In the control group, there were 8 children with sigmatism and 6 children with rhotacism; 7 children had multiple articulation disorders.

In the AOB group and control group together, there were 37 children with articulation disorders. Among them there were 31 children with resting tongue posture on the floor of the mouth. In 38 children without articulation disorders, there were only 6 children with improper resting tongue posture ($p < 0.001$).

[Table 2](#) compares the AOB and the control group children with respect to the general data, the resting posture of the tongue and the occurrence of articulation disorders detected by orthodontist and speech therapist. There was a significant difference between the groups in age, resting tongue posture, and occurrence of articulation disorders.

Table 2

Comparison of the general data, ultrasound-assessed resting tongue posture, and the prevalence of articulation disorders between the anterior open bite group (N = 32) and the control group (N = 43)

Parameter	AOB group (N = 32)	Control group (N = 43)	p
Male gender ¹	17 (53%)	20 (46%)	0.571

Parameter	AOB group (N = 32)	Control group (N = 43)	p
Age (years) ²	4.9 (1.0)	4.3 (0.3)	< 0.001
Articulation disorder (speech therapist's assessment)	27 (84%)	10 (23%)	< 0.001
Improper resting tongue posture (3DUS)	26 (81%)	11 (26%)	0.001

AOB = anterior open bite; 3D US = three-dimensional ultrasound

¹For categorical variables number and percentage is given

²for numerical mean and SD

There was a significant difference in age between the AOB group and control group. For further analysis, age adjustment was performed. The significant variables were included into two multiple logistic regression models: model 1 (age, improper tongue posture) and model 2 (age, improper tongue posture, presence of articulation disorders). The results for model 1 showed that the improper resting tongue posture (according to the US examination) and the presence of AOB were associated. The children with the tongue posture on the floor of the mouth had higher odds ratios for the presence of AOB (OR 14.63, 95% CI 4.08–52.39, and $p < 0.001$). When articulation disorders were included (model 2), the odds ratios for the presence of AOB became insignificant for the children with improper resting tongue posture (OR 3.16, 95% CI 0.59–16.79, and $p = 0.177$). This was likely a consequence of a strong association between the tongue posture and articulation disorders. Apparently, it is the presence of articulation disorders, strongly associated with improper tongue posture, that has the most significant correlation with the presence of AOB (OR 13.79, 95% CI 2.56–74.23, and $p = 0.002$).

[Go to:](#)

Discussion

Clinical examination of the tongue posture and function is an important part of functional diagnostics in orthodontics and dentofacial orthopaedics as well as in the field of ENT. However, it is difficult to get objective findings of tongue posture during clinical examination in small children because of their cooperation and anatomical characteristics of the orofacial area.[17](#)

According to Graber *et al.*[18](#) the assessment of tongue posture during clinical examination should be performed in the physiological resting position of the mandible and the examiner should slightly open the lips of the examinee to register the posture of the tongue in the oral cavity. However, even a slightest touch of the lips could represent a stimulus for the examinee to drop the tongue to the mouth floor and in the direction of the touched lips.[16,19](#)

Many studies investigated tongue function during swallowing and speech by using radio-cinematography,[20,21](#) magnetic resonance,[22](#) and 2-dimensional ultrasonography,[19,23](#) while tongue posture has been evaluated by using lateral cephalograms and computed tomography.[24](#) The disadvantage of these diagnostic procedures is radiation exposure, which contraindicates these methods to be used in small still growing children and disables frequent repetitions of the proposed methods. Ultrasonography is a noninvasive method and is widely used in

many fields in medicine, obstetrics, gynecology, perinatology, and pediatrics.[25,26,27](#) Three-dimensional ultrasonography greatly improved and nowadays permits acquisition of high resolution images. It was also used in the studies in the orofacial area (e.g. in adult patients after partial resection of the tongue).[28,29](#) However, data about 3D surface morphology of anatomically normal but diversely postured tongues at rest in growing children have only been performed in the field of orthodontics.[17](#)

In the present study, 3D ultrasonography was used for the first time in the assessment of tongue posture in the early stage of growth and development in preschool children with articulation disorders and AOB. Furthermore, in this study the clinical assessment of the tongue posture under standard conditions was performed independently by two different specialists, the experts in functional diagnostics of the orofacial area, by the ENT specialist and by the orthodontist. Their assessments were compared to the 3DUS examination performed by an experienced radiologist. The results of all three examiners using different methods were found to be in agreement (McNemar's test, $p = 0.180$ and $p = 0.549$, respectively) ([Figure 3](#)). However, the 3DUS method objectively revealed the largest number of children with low tongue posture, which proved the validity of this diagnostic tool. To the best of our knowledge, this study was the first one to evaluate the reliability between the clinical ENT and orthodontic assessment of the tongue posture, and compared to the 3DUS assessment.

With the use of 3DUS, 81.2% of the children with AOB were found to have improper tongue posture on the mouth floor, while in the control group subjects, the irregular tongue posture was registered only in 25.6% of the examined children (McNemar's test, $p < 0.001$). The interpretation of our findings confirmed that improper tongue posture on the mouth floor is prevalent in children with AOB.

Furthermore, the present study found similar results of the irregular tongue posture in control group subjects (25,6 %) without malocclusion as reported previously in the study by Volk *et al.*[17](#) The two studies demonstrated very clearly that 3DUS can be used for the assessment of tongue posture in growing children. The main advantage of the 3DUS method is its non-invasive character, which enables that repetitions of the examination can frequently be performed.

The results suggested that besides the known risk factors (long bottle feeding, finger sucking) the resting tongue posture on the mouth floor is crucial for the development of AOB. The important factors for the development of AOB can be impaired nasal breathing and enlarged adenoids which were detected in almost two thirds of the AOB group. Unfortunately, a comparison with the control group was not possible because a considerable number of children from control group had upper airway infection at the time of ENT examination. The oedema of the nasal mucosa and the size of adenoids as a consequence of viral infection influenced the patency of the nose, possibility of nasal breathing, lip closure and resting posture of the tongue in the oral cavity. Therefore, the signs of the infection prevented a comparison of the AOB group and control group at the time when the ENT examination took place.

On the other hand, when we compared the data on child's nasal breathing during day according to the parents' report between the children with AOB and the other children without AOB, the difference was close to the significant values. This result suggested that the cause for improper tongue posture might be an insufficient patency of the nose in the time of jaws' development resulting in a malocclusion.

The majority of the children with AOB (84.4%) had articulation disorders in comparison to the control group children (23.2%). One of the reasons for such a high number of children with articulation disorders may be a result of individual stage of growth and development of articulation. At the age of 5-6 years late maturation articulation disorders can still be observed.¹¹ However, when children from both groups were observed, the children without articulation disorders had a statistically significantly lower percentage of the improper tongue posture (15.8%) than the children with articulation disorders (83.8%). This strong association between AOB, improper resting tongue posture, and articulation disorders was found to be one of the main clinically relevant results of this study. It can therefore be concluded that these factors are important risk factors for articulation disorders of the sounds performed in the anterior part of the mouth.

From this point of view, a precise functional diagnostics is very important in the assessment of early treatment needs for AOB in the deciduous dentition in order to implement interceptive and preventative actions, and to provide optimal balanced condition in the oral cavity for proper articulation development.

The 3DUS assessment of tongue posture was found to be an important and valuable tool for the objective assessment of resting tongue posture not only in the etiology of malocclusion and articulation disorders, but also to further objectify the efficiency of early orthodontic treatment, assessment of the success of treatment, and consequently to evaluate successful long-term oral rehabilitation. The main advantage of the proposed method is its non-invasive character. 3DUS proved to be the most valid and reliable method to assess improper resting tongue posture as it most objectively identified the highest number of children with improper resting posture of the tongue in the oral cavity. From the clinician's point of view, it is also relatively simple, quick, repeatable and child-friendly method.

[Go to:](#)

Conclusions

This study demonstrated that 3DUS is an objective, reliable, non-invasive, radiation free, non timeconsuming, and child-friendly diagnostic tool for the assessment of tongue posture in small children. Furthermore, 3DUS identified the highest number of incorrect tongue postures, which was highly related to articulation disorders in preschool children with malocclusion. Therefore, every clinical examination of orofacial functions in preschool children should be focused on proper resting tongue posture. The child and his/her parents should get the early information about the correct resting tongue posture in the mouth. In this way, an optimal condition in the oral cavity for proper tongue maturation and articulation development can be created.

The 3DUS was found to be the most objective method to identify tongue posture in growing children and could become in the future an important tool in functional diagnostics in radiology, ENT as well as in orthodontics and dentofacial orthopedics.

[Go to:](#)

Acknowledgments

The authors would like to thank Dr Alexei Zhurov and Dr Greg Huang for their valuable comments and suggestions that helped to improve this paper. This work was financially supported from the state budget by the Slovenian Research Agency [Grants: P3-0374; P3-0289; P3-0307].

[Go to:](#)

Notes

[Go to:](#)

Disclosure

No potential conflicts of interest were disclosed.

[Go to:](#)

References

1. Ballanti F, Franchi L, Cozza P.. Transverse Dentoskeletal Features of Anterior Open Bite in the Mixed Dentition A Morphometric Study on Posteroanterior Films. *Angle Orthod.* 2009;79:615–20. doi: 10.2319/071808-375.1. [[PubMed](#)] [[CrossRef](#)]
2. Mucedero M, Fusaroli D, Franchi L, Pavoni C, Cozza P, Lione R. Long-term evaluation of rapid maxillary expansion and bite-block therapy in open bite growing subjects: A controlled clinical study. *Angle Orthod.* 2018;88:523–9. doi: 10.2319/102717-728.1. [[PubMed](#)] [[CrossRef](#)]
3. Proffit WR.. Equilibrium theory revisited: factors influencing position of the teeth. *Angle Orthod.* 1978;48:175–86. doi: 10.1043/0003-3219(1978)048<0175ETRFIP>2.0.CO;2. [[PubMed](#)] [[CrossRef](#)]
4. Greenlee GM, Huang GJ, Chen SSH, Chen JD, Koepsell T, Hujoel P.. Stability of treatment for anterior open-bite malocclusion: A meta-analysis. *Am J Orthod Dentofac.* 2011;139:154–69. doi: 10.1016/j.ajodo.2010.10.019. [[PubMed](#)] [[CrossRef](#)]
5. Ngan P, Fields HW.. Open bite: a review of etiology and management. *Pediatr Dent.* 1997;19:91–8. [[PubMed](#)]
6. Silvestrini-Biavati A, Salamone S, Silvestrini-Biavati F, Agostino P, Ugolini A.. Anterior open-bite and sucking habits in Italian preschool children. *Eur J Paediatr Dent.* 2016;17:43–6. [[PubMed](#)]
7. Zuroff JP, Chen SH, Shapiro PA, Little RM, Joondeph DR, Huang GJ.. Orthodontic treatment of anterior open-bite malocclusion: Stability 10 years postretention. *Am J Orthod Dentofac.* 2010;137 doi: 10.1016/j.ajodo.2009.06.020. [[PubMed](#)] [[CrossRef](#)]
8. Ovsenik M.. Incorrect orofacial functions until 5 years of age and their association with posterior crossbite. *Am J Orthod Dentofac.* 2009;136:375–81. doi: 10.1016/j.ajodo.2008.03.018. [[PubMed](#)] [[CrossRef](#)]
9. Johnson NCL, Sandy JR.. Tooth position and speech - is there a relationship? *Angle Orthod.* 1999;69:306–10. doi: 10.1043/0003-3219(1999)069<0306tpasit>2.3.co;2. [[PubMed](#)] [[CrossRef](#)]
10. Stahl F, Grabowski R, Gaebel M, Kundt G.. Relationship between occlusal findings and orofacial myofunctional status in primary and mixed dentition - Part II: Prevalence of orofacial dysfunctions. *J Orofac Orthop.* 2007;68:74–90. doi: 10.1007/s00056-007-2606-9. [[PubMed](#)] [[CrossRef](#)]
11. Farronato G, Giannini L, Riva R, Galbiati G, Maspero C.. Correlations between malocclusions and dyslalias. *Eur J Paediatr Dent.* 2012;13:13–8. [[PubMed](#)]
12. Barbič U, Verdenik I, Marolt Mušič M, Ihan Hren N.. Three - dimensional ultrasound evaluation of tongue volume. *Zdrav Vest.* 2016;85:228–36. doi: 10.6016/ZdravVestn.1477. [[CrossRef](#)]

13. Hiiemae KM, Palmer JB.. Tongue movements in feeding and speech. *Crit Rev Oral Biol Med.* 2003;14:413–29. 14/6/413[pii] [[PubMed](#)]
14. Moss JP. The use of three-dimensional imaging in orthodontics. *Eur J Orthod.* 2006;28:416–25. doi: 10.1093/ejo/cjl025. [[PubMed](#)] [[CrossRef](#)]
15. Ovsenik M, Volk J, Marolt MM.. A 2D ultrasound evaluation of swallowing in children with unilateral posterior crossbite. *Eur J Orthodont.* 2014;36:665–71. doi: 10.1093/ejo/cjt028. [[PubMed](#)] [[CrossRef](#)]
16. Peng CL, Jost-Brinkmann PG, Yoshida N, Miethke RR, Lin CT.. Differential diagnosis between infantile and mature swallowing with ultrasonography. *Eur J Orthodont.* 2003;25:451–6. doi: 10.1093/Ejo/25.5.451. [[PubMed](#)] [[CrossRef](#)]
17. Volk J, Kadivec M, Music MM, Ovsenik M.. Three-dimensional ultrasound diagnostics of tongue posture in children with unilateral posterior crossbite. *Am J Orthod Dentofacial Orthop.* 2010;138:608–12. doi: 10.1016/j.ajodo.2008.12.028. [[PubMed](#)] [[CrossRef](#)]
18. Graber TM, Rakosi T, Petrovic AG. *Dentofacial orthopedics with functional appliances.* St. Louis: Mosby; 1985.
19. Peng CL, Jost-Brinkmann PG, Yoshida N, Chou HH, Lin CT.. Comparison of tongue functions between mature and tongue-thrust swallowing - an ultrasound investigation. *Am J Orthod Dentofac.* 2004;125:562–70. doi: 10.1016/j.ajodo.2003.06.003. [[PubMed](#)] [[CrossRef](#)]
20. Ekberg O, Hillarp B.. Radiologic Evaluation of the Oral Stage of Swallowing. *Acta Radiol Diagn (Stockh)* 1986;27:533–7. doi: 10.1177/028418518602700508. [[PubMed](#)] [[CrossRef](#)]
21. Fujiki T, Inoue M, Miyawaki S, Nagasaki T, Tanimoto K, Takano-Yamamoto T.. Relationship between maxillofacial morphology and deglutitive tongue movement in patients with anterior open bite. *Am J Orthod Dentofac.* 2004;125:160–7. doi: 10.1016/j.ajodo.2003.03.009. [[PubMed](#)] [[CrossRef](#)]
22. Lauder R, Muhl ZF.. Estimation of Tongue Volume from Magnetic-Resonance-Imaging. *Angle Orthod.* 1991;61:175–84. doi: 10.1043/0003-3219(1991)061<0175eotvfm>2.0.co;2. [[PubMed](#)] [[CrossRef](#)]
23. Peng CL, Jost-Brinkmann PG, Miethke RR, Lin CT.. Ultrasonographic measurement of tongue movement during swallowing. *J Ultras Med.* 2000;19:15–20. [[PubMed](#)]
24. Lowe AA, Fleetham JA, Adachi S, Ryan CF.. Cephalometric and computed tomographic predictors of obstructive sleep-apnea severity. *Am J Orthod Dentofac.* 1995;107:589–95. doi: 10.1016/S0889-5406(95)70101-X. [[PubMed](#)] [[CrossRef](#)]
25. De Candia A, Como G, Passon P, Pedace E, Bazzocchi M.. Sonographic findings in glomus tympanicum tumor. *J Clin Ultrasound.* 2002;30:236–40. doi: 10.1002/jcu.10058. [[PubMed](#)] [[CrossRef](#)]
26. Pavcec Z, Zokalj I, Saghir H, Pal A, Roic G. Doppler ultrasound in the diagnosis and follow-up of the muscle rupture and an arteriovenous fistula of the thigh in 12 year boy. *Radiol Oncol.* 2006;40:211–5.
27. Vegar-Zubovic S, Lincender L, Dizdarevic S, Sefic I, Dalagija F.. Ultrasound signs of acute appendicitis in children - clinical application. *clinical application. Radiol Oncol.* 2005;39:15–21+821.

28. Bressmann T, Ackloo E, Heng CL, Irish JC.. Quantitative three-dimensional ultrasound imaging of partially resected tongues. *Otolaryng Head Neck*. 2007;136:799–805. doi: 10.1016/j.otohns.2006.11.022. [[PubMed](#)] [[CrossRef](#)]
29. Bressmann T, Thind P, Uy C, Bollig C, Gilbert RW, Irish JC.. Quantitative three-dimensional ultrasound analysis of tongue protrusion, grooving and symmetry: Data from 12 normal speakers and a partial glossectomee. *Clin Linguist Phonet*. 2005;19:573–88. doi: 10.1080/02699200500113947. [[PubMed](#)] [[CrossRef](#)]